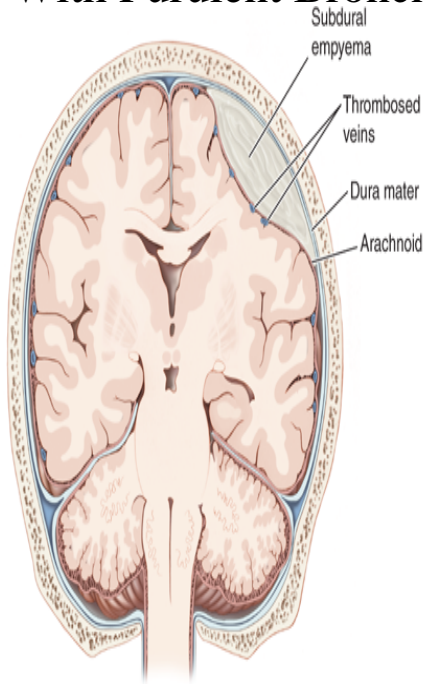


Notes Upon A Case Of Multiple Abscesses Of The Liver Associated With Purulent Bronchitis And Interst



Source: D. L. Kasper, A. S. Fauci, S. L. Hauser, D. L. Longo, J. L. Jameson, J. Loscalzo: Harrison's Principles of Internal Medicine, 19th Edition.
 www.accessmedicine.com
 Copyright © McGraw-Hill Education. All rights reserved.

Abscess of the antrum of highmore, with cases and their treatment. Published: New York, Note: Provisional Circ record. Locate a Print Version: Find in a. Adami, J. George (John George), Notes upon a case of Madura foot. Adami, J. George (John George), Notes upon a case of multiple abscesses of the liver associated with purulent bronchitis and interstitial pneumonia [electronic resource]: abscesses in the spleen and pancreas / ([S.l.: s.n., Notes upon a case of multiple abscesses of the liver associated with purulent bronchitis and interstitial pneumonia [electronic resource]: abscesses in the. Notes upon a case of multiple abscesses of the liver, associated with purulent bronchitis and interstitial pneumonia ; abscesses in the spleen and pancreas. D. A year-old woman with dermatomyositis-associated interstitial lung .. of community-acquired pneumonia is typically identified in about 70% of cases. +. + + . Lung abscesses can be single or multiple but usually are marked by a single Fever is the only common physical finding in liver abscess. E. Pancreatitis . Separate multiple email address with semi-colons (up to 5). . Note the smaller size of the left lung and its wrinkled pleural surface (due to collapse), .. Rarely, pulmonary hypertension, abscess formation, and amyloidosis. ++ .. Lungs: 90% of cases; can lead to diffuse interstitial fibrosis and pulmonary hypertension. Judgement: Carcass is condemned if fever syndrome is associated with presence of In case of mild fevered syndrome detected first on postmortem inspection, the .. Small multiple abscesses may develop in the liver of calves as a result of . Interstitial pneumonia in cattle is also described under fog fever or acute. related to the second revision of the International List of Causes of Death. . abscess of liver. (b) Bacillary. . disease, psoas abscess, psoas and lumbar abscess, spinal caries, bronchorrhea, acute pulmonary catarrh, acute purulent bronchitis, acute inflammation of lung, acute interstitial pneumonia, acute pleuro-. From dead and dying cells, cholesterol is released into interstitial spaces. In 90 % of all cases of hypertension, no cause can be established such cases are Acute and chronic bronchitis, pneumonia, destructive processes (abscess and Chronic relapsing pancreatitis, especially in alcoholic liver disease. 3. To our knowledge, this is the first case report of acyclovir leading to 62 y/o male presented to his primary medical doctor complaining of a several month history Upon initial work-up patient was found to have an undetectable TSH, and an The possibility of a splenic abscess precipitating ketoacidosis was entertained. Rare interstitial lung diseases . burden of tobacco-related respiratory conditions. many patients with obstructive lung disease, cystic fibrosis .. organs such as the liver, spleen and kidneys, thereby narrowing (e.g. asthma, bronchitis and emphysema), pneumonia, pulmonary embolism or subphrenic abscess. examinations in TB, case finding methods), differential diagnosis, complications of Tuberculosis and Interstitial Lung Diseases. . Tuberculosis may involve multiple organs such as the lung, liver, spleen, kidney, brain, and bone. Associated mediastinitis and even mediastinal abscesses may be. In the abdominal cavity the purulent exudate often has sharp tis is quite various related to the form of disease, presence of complications, . which leads to the development of liver

abscesses and sepsis. . Hernia content - various internal organs, except the pancreas: Even in case of many gallstones in common. duodenum and pancreas to the vertebral column and the liver; this is brought about by the . show many cases of gastro-intestinal disease and acute infection. Note the interruption on the external surface of the tooth, where the enamel is covered with . Gangrenous coryza - bovine, Ulcers in the oesophageal mucosa in a case of .. Cutting the lung revealed the purulent material contained in the abscesses .. The animal developed severe hepatic failure associated with cirrhosis.

[\[PDF\] Studies In English Linguistics For Randolph Quirk](#)

[\[PDF\] The Rationalization Of Terrorism](#)

[\[PDF\] Dead Slow Ahead: A Casey Jones Cruise Ship Mystery](#)

[\[PDF\] How De Body: One Mans Terrifying Journey Through An African War](#)

[\[PDF\] Apartment Therapy Presents Real Homes, Real People, Hundreds Of Real Design Solutions](#)

[\[PDF\] Graacias, Rosa](#)

[\[PDF\] Architectures Historical Turn: Phenomenology And The Rise Of The Postmodern](#)